

# Abobotulinum toxin A and fillers for facial rejuvenation: My experience and technique

Redaelli Alessio<sup>1\*</sup> and Battistella Melania<sup>2</sup>

<sup>1</sup>Cosmetic Medical Department, Visconti di Modrone Medical Center, Milan, Italy, Via Visconti di Modrone 7, Milan, Italy

<sup>2</sup>Research and Development Department, General Project, Florence, Italy

## Abstract

**Background:** Botulinum toxin A has been in use for more than 20 years for aesthetics. In Italy was firstly approved in 2004. From the very first moment I was using Abobolotimun Toxin A (Dysport and Azzalure) for aesthetical reasons. The use of Abobotulinum Toxin A (AboTA), the conversion rate with other toxins, its dilution and units used are still today not totally known by many specialists of the field.

**Objective:** assess and update the perfect use of AboTA and fillers for facial rejuvenation

**Material and methods:** literature has been reviewed (Pub Med, Med line, books) using main database and published books and compared with the personal modalities of using Speywood units of AboTA for cosmetical indications in face. Fillers are very important in the restoration of lost volumes.

**Discussion:** AboTA is a safe and very good drug for wrinkling treatment. All side effects are related to bad techniques, mistakes in the use, depth of injections. If well used, AboTA is very safe and a very well performing drug. The integration with fillers is highly recommended to achieve natural and effective results. Only best fillers must be used.

**Conclusions:** AboTA, is a safe drug, with very good results. Side effects can be avoided only with a perfect anatomical knowledge, perfect depth of injections and prudential utilization of Units. Fillers must be used safely and the use of Hyaluronidase must be known by all aesthetic doctors.

## Introduction

Botulinum Toxin A was introduced in the European Market in the '90ies. Then after some years, deregulated, OnaBotulinum Toxin A was approved in 2004 for cosmetical uses, while Abobotulinum Toxin A (AboTA) in 2010 and Incobotulinum Toxin A in 2011.

AboTA is present nowadays quit all over the world with a very good Market Share, but especially among neurologists and ophthalmologists.

Its use in aesthetic medicine is not so diffused and the knowledge among doctors can be improved. Over this its use with fillers appears to be very indicated and synergic indications that allow patients and doctors to get very good results [1-3].

In this article the scientific details of AboTA have been reminded, an updated bibliography assessed and the personal details of techniques with AboTA and fillers explained.

## Materials and methods

AboTA has a trade name of Dysport® 300 and 500U. In Europe it is distributed as Azzalure®. There is no difference between these different brand names [1,4,5].

The active chain of Botulinum Toxin A is always the same and weights 150 KDa. Instead the total content of this protein is slightly different (0.73 ng for OnaTA, 0.75 for AboTA and 0.44 for IncoTA).

In the formulations of BTxA there are also some nontoxic accessory proteins (NAPs) joined to the 150-kD active chain.

AboTA was approved by US FDA in 2009 for moderate-to-severe glabellar lines [4]. In Russian countries the on label indication, supported by Ipsen Company is the upper third of the face. All other indications are based on personal experience of different authors [5].

Even if it is not totally confirmed by the literature, AboTA has a greater diffusion confirmed in my clinical practice and my conversion ratio is quit always 2.5U Dysport: 1U Botox. A greater conversion ratio 3:1 in my opinion leads to more side effects, confirmed also by many studies [6].

Dilution of AboTA is another discussed task. Quit 13 years ago I already published my philosophy of a very low dilution [7] to reduce spreading and nowadays the best dilution in my opinion remains around 2.5 ml of normal saline for 500U. But in many indications I dilute around 3 ml, while sometimes I prefer to reduce diffusion reducing dilution also up to 1.5 ml.

Fillers discussed in this publication are produced by Filorga, XHa3, Volume and MHa18. Also new range of fillers, Art Fillers Volume, Lips, Universal and fine lines have been discussed and remain in the opinion

**Correspondence to:** Redaelli Alessio, Cosmetic Medical Department, Visconti di Modrone Medical Center, Milan, Italy, Via Visconti di Modrone 7, Milan, Italy, E-mail: mail@docredaelli.com, Website: www.docredaelli.com

**Key words:** Abobotulinum toxin A, Dysport, Azzalure, Mimical wrinkling, XHa, Art Filler

**Received:** April 07, 2017; **Accepted:** April 27, 2017; **Published:** April 29, 2017

of the author among best fillers on the market. To avoid dramatic ischemic problems the use of Hyaluronidase must be known and available immediately in all aesthetic clinics in the world.

## Study of patients

Patients are studied in the first moment of the visit while they move naturally and the doctor can see the origin of the aesthetical problem: Mimical, volumetrical or of reduction of skin tonus [2,3].

The face is divided in three thirds, from Trichion to glabella, from glabella to nasal spine and from nasal spine to menton. These areas of the face can be easily assessed as seen in the picture below, with every possible instrument, a scissor in this case!

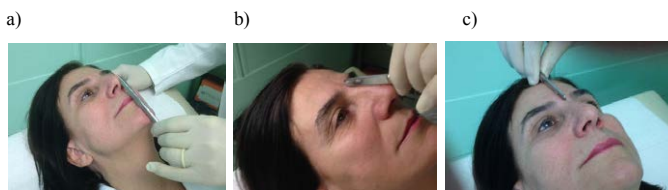


Figure 1. Practical assessment of horizontal areas of the face.

## General considerations in different areas of the face

### Upper third

Mimical movements are normally predominant and so in the majority of cases the better solution for forehead wrinkles is botulinum toxin type A (Dysport®) [4,5]. The treatment then of depressor muscles of this area, Procerus, corrugator and Orbicularis Oculi are well known and the On Label indication of AboTA [1,2,8,9]. Sometimes it is possible see pronounced orbital bones with a complementary depressed area over the eyebrows. In these cases volumetrical dermal fillers can be used for a volumetrical correction. Sometimes can be present a reduction of hydration and fine wrinkles, primary reduced with BTxA that can be improved also with a fine non cross linked filler. In this case M-HA 18° can be the perfect choice. Also eyebrows, sometimes, can be ptotic and reduced in volumization. Also in these cases soft fillers can be the perfect solution. Being a dangerous area with many nerves and vessels [5,6], it is better use always on eyebrows blunt cannulas (best 25G x 50 mm).

Best Indications for AboTA are:

- glabellar area
- crow's feet lines
- forehead

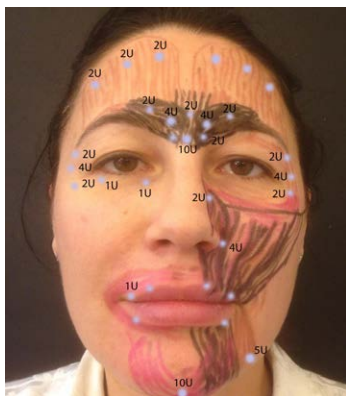


Figure 2. Average Units used by the Author for "On Label" and "Off Label" indications.

It is very good indication also eyebrow lifting, indicated when there is a tension in eyebrow depressor muscles.

It is always very important in glabellar area avoid the diffusion of AboTA in the elevator muscle of the forehead, the frontalis muscle. For this reason the procerus must be injected deeply and the corrugators also, paying attention to avoid the diffusion in superficial frontalis fibers.

Fillers will be used in volumetrical problems and fine fillers (Art Filler Fine lines or MHa18 for example) for superficial texture improvement.

Great attention must be put in avoiding injection of glabellar artery and always in the periocular area for the presence of many arteries and veins directly connected with the ocular network with possible dramatic consequences. [5,10-12].

In case of ischemic complication always after HA injections, the usual suggestion and mine personal remains [13]:

- Long and immediate massage and immediately if no solution of the problem...
- Hyaluronidase (as **Vitraxe**, ISTA, Irvine, California or Hyalase, 1500 IU or Hylenex 150 IU or Hylase Dessau®)
- Nitro-glycerine plasters (5mg) or creams locally if impossible to get a result.

Hyaluronidase is sold in vials normally 1500 IU. In some countries there are vials 150 IU, sometimes galenic as in Italy, 150 IU as well. So every country must have the allowed product.

In case of vials 1500 IU what I do is: 1500U (Frigo 2-8°) are diluted with 1 ml normal saline.

With a syringe 1 ml we take 0.1 (150 IU) and we dilute again it up to 1 ml

### 0.1 ml = 15 IU

Normally boluses of 15 IU each, up to 150,200 IU are immediately injected in the ischemic area to try to dissolve the HA injected in the artery [2,9,14]. The result is immediate!

It is of paramount importance, in case of ischemical problems, inject immediately the enzyme and that the patients know to come back in case of problems immediately and not after few days.

Hyaluronidase immediately dissolves HA and can be of great help in avoiding this type of side effects.

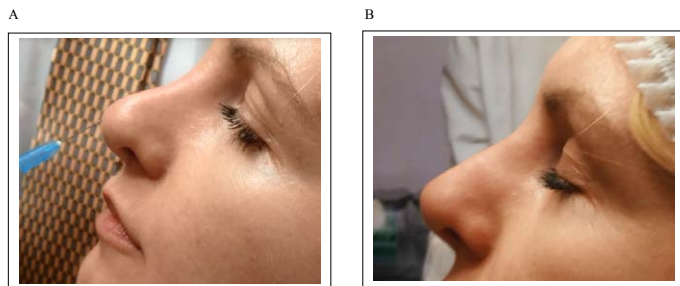
### Middle third

Reduction of volumes and their dislocation downward are main characteristics of this part of the face [5]. Volumetrical fillers are the best treatment for this part of the face. There are few mimical areas, especially crow's feet lines and bunny lines where the use of AboTA gives a good result. In this area the nose remains one of the best indications. It divides the face in 2 parts and gives the characterization of all the face. Everybody who followed one of my master classes knows how much importance I give to this organ. Mimical plunging tips can be treated with Dysport®, while nasal bridge deformities can be improved sometimes very easily with cross linked fillers (FILORGA X-HA 3° and FILORGA X-HA° Volume and the new range of Art Fillers, Volume and Universal). Cannula here is also mandatory for a number of terminal vessels present in the area. I strongly suggest all the

readers to see the different possibilities but overall, adopt all possible measures to avoid intra-arterial injections that can lead to dramatic side effects.

The results on the nose are immediate and sometimes really impressive. Post-surgical cases are a very interesting indication, as visible in Fig.3. They can last for an average of 1.5-2 years

Another very dangerous and difficult area is tear through. The presence of facial vein and many arteries make this area dangerous [10]. Cannula is mandatory to avoid problems. The entry point can be at the end of jugal groove, a strategic entry point also for nasolabial folds, cheeks and even marionette lines. Always I use thick cannulas, at least 25G or 23G. Never had I used thinner cannulas, dangerous as needles.



**Figure 3.** Nasal correction in a post-surgical case (15 years before!) before (a) and after (b).

Best dilution of AboTA in this area remains 2.5 ml normal saline for 500U.

Best indications for AboTA in this area are:

- Bunny lines
- Nasal tip drooping

### Lower third

The main problem for Lower third of the face is volumetrical reduction, sagging and ptosis of the tissues. For the volumetrical reduction of the cheeks, and especially when dehydration is present, dermal fillers will be the first indication (FILORGA X-HA 3° and FILORGA X-HA° Volume, M-HA 18°). Dermal fillers remain also indicated for improvement of mandibular line, lip corners and marionette lines, chin area definition. Volumetrical problems of the lips foresee the main indication in the use of reticulated fillers as FILORGA X-HA 3° and Art Filler Universal. But we must not forget that lips are a very important mimical area where BTxA can be the first indication. Therefore, the use of botulinum toxin (Dysport®) in this area depends on expert's opinion and individual characteristics of the patient. Except for the lips, in the most part of cases, in the inferior third of the face, BTxA is only of help and complementary to the use of dermal fillers or threads. Surgery is also a very good indication even if much more invasive [3].

Naso labial folds are mainly a volumetrical problem but we can't forget that sometimes the mimical origin is possible and in these rare cases AboTA is the right procedure [1,3,5]. The presence of important arteries says as to be very prudent, use maybe cannulas, better than needles and know how to use hyaluronidase in any possible rare case of ischemia [3,5,10,15,13].

Lips treatment with AboTA must be very conservative and I do not exceed in the great majority of patients 4 point on the vermilion edge with no more than 1U x point, intradermal, very superficial.

Best dilution of AboTA in this area remains 2.5 ml normal saline for 500U [5].

Best indications for AboTA in the inferior third of the face are:

- Mimical Code bar wrinkles
- Mimical marionette lines
- Platysmal bands
- Mesodysport for mimical cheeks lines

A particular very new indication are quadralized patients, with an important masseter hypertrophy. AboTA represents a gold standard treatment for the volumetrical reduction of this muscle. I inject normally 3 or 4 point with 15U AboTA each. Preferred dilution is 3 ml normal saline for 500U.

### Discussion

According with patients' problems we can have nowadays a huge number of possible techniques to be used.

For sure AboTA and fillers are among the most important techniques for facial rejuvenation: while ABOTA is effective to reduce the mimicity of the face, fillers can be used to rebalance and volumize the face. The defects in the superior third of the face are quit always mimical and for this reason AboTA is the most indicated technique. There are few cases where a volumetrical problem can appear, especially in patients with prominent orbital bones. In these rare cases the use of volumetrical filler with cannula can represent the indicated technique.

The middle third of the face is normally characterized by the reduction of volumes and dislocation of tissues downward. Fillers are more indicated while AboTA can be a good indication for bunny lines and nasal tip improvement. Nasal bridge enhancement is a very good and genial possibility in minor defects with very good and long lasting results. Ischemical problems, frequent with needles, can be reduced to a very low rate with the use of cannulas.

In the inferior third of the face, sagging and dislocation of tissues are predominant and fillers are the best materials to be used. AboTA can be a synergistic technique but can't be the gold standard. New emerging techniques can be indicated. Among these, in the inferior third of the face threading can be a very good and indicated option.

### Conclusions

AboTA and fillers are very interesting synergic techniques to achieve natural results in our patients. The goal is not get frozen patients but reduce overloaded mimical movements and rebalance reduced volumes in the right area.

AboTA confirms its very good possible use also for aesthetical indications with very good and long lasting results. Filorga Fillers are for sure among best fillers on the market and allow us to achieve very safe and natural results.

The preparation of doctors is of main importance especially to avoid dramatic consequences, especially ischemical, after the use of Hyaluronic Acid. For this rare but possible evenience all aesthetic doctors should be aware of the use of Hyaluronidase, available nowadays quit everywhere. Right dilution when needed and right injected U can resolve immediately dramatic side effects.

## Disclosure

The author is speaker for Ipsen and Filorga and other Pharmaceutical companies. This article was not supported by anybody and what is written inside reflects own experience of the author that has total responsibility for the contents.

## References

1. Redaelli A (2014) TxA in aesthetic Medicine, for hyperhidrosis and in odontostomatology. Basic Principles and clinical practice. Second revised edition, OEO Firenze.
2. Hessel D, Brum C, Porto MD, Soirefmann M, Siega C, et al. (2013) Quality of life and satisfaction of patients after full-face injections of abobotulinum toxin type A: A randomized, phase IV clinical trial. *J Drugs Dermatol* 12: 1363-1367.[Crossref]
3. Redaelli A.: Facial Aging, medical, surgical and odontostomatological solutions. 2011, OEO Firenze
4. <http://www.fda.gov/Drugs/DrugSafety/PostmarketDrugSafetyInformationforPatient-sandProviders/DrugSafetyInformationforHealthcareProfessionals/ucm174949.htm>.
5. Redaelli A (2016) Complex correction of facial aging with Dysport and Filorga Fillers. Philosophy. (in Russian language) Medpress-inform.
6. Scaglione F (2016) Conversion Ratio between Botox®, Dysport®, and Xeomin® in Clinical Practice. *Toxins (Basel)* 8.[Crossref]
7. Redaelli A, Forte R (2003) Botulinum toxin dilution: our technique. *J Cosmet Laser Ther* 5: 218-219.[Crossref]
8. Kashkoui MB1, Amani A, Jamshidian-Tehrani M, Yousefi S, Jazayeri AA (2014) Eighteen-point abobotulinum toxin a upper face rejuvenation: an eye plastic perspective on 845 subjects. *Ophthal Plast Reconstr Surg* 30: 219-224.[Crossref]
9. Lorenc ZP1, Kenkel JM, Fagien S, Hirmand H, Nestor MS, et al. (2013) A review of AbobotulinumtoxinA (Dysport). *Aesthet Surg J* 33: 13S-7S.[Crossref]
10. Saban Y (2016) Anatomie du visage et du cou, Masson Elsevier
11. Park KH, Kim YK, Woo SJ, Kang SW, Lee WK, et al.(2014) Iatrogenic Occlusion of the Ophthalmic Artery after Cosmetic Facial Filler Injections. A National Survey by the Korean Retina Society. *JAMA Ophthalmol* 132: 714-723.[Crossref]
12. Glaich AS, Cohen JL, Goldberg LH (2006) Injection necrosis of the glabella: protocol for prevention and treatment after use of dermal fillers. *Dermatol Surg* 32: 276-281. [Crossref]
13. Hilton S, Schrupf H, Buhren BA, Bölke E, Gerber PA (2014) Hyaluronidase injection for the treatment of eyelid edema: a retrospective analysis of 20 patients. *Eur J Med Res* 19: 30.[Crossref]
14. Happak W (1997) Human facial muscles: dimensions, motor endplate distribution, and presence of muscle fibers with multiple motor endplates. *Anat Rec* 249: 276-284. [Crossref]
15. Grunebaum LD, BogdanAllemann I, Dayan S, Mandy S, Baumann L (2009) The risk of alar necrosis associated with dermal filler injection. *Dermatol Surg* 35 Suppl 2: 1635-1640.[Crossref]