

Primary malignant lymphoma of the uvula

Takeshi Kusunoki^{1*}, Hirotomo Homma¹, Yoshinobu Kidokoro¹, Aya Yanai¹, Ryo Wada² and Katsuhisa Ikeda³

¹Department of Otorhinolaryngology, Juntendo University of Medicine, Shizuoka Hospital, Japan

²Department of Pathology, Juntendo University of Medicine, Shizuoka hospital, Japan

³Department of Otorhinolaryngology, Juntendo University of Medicine, Faculty of Medicine, Japan

Abstract

We experienced a very rare case of primary malignant lymphoma of the uvula. The patient was an 80-year-old Japanese woman with a one month history of oral discomfort. She had a uvular mass occupying the oropharyngeal space and received surgical treatment. Follicular lymphoma was diagnosed by immunohistochemical staining. In the general examination, PET-CT showed no abnormal accumulation in the body, and the marrow chromosome examination results were normal. From the above results, our case was considered stage IA (UICC) and we added postoperative radiotherapy (33.6Gy). At 3 years after the radiation therapy, no recurrence or metastasis was found.

Introduction

Malignant neoplasms of the uvula are rare, and the most common histopathology is squamous cell carcinoma [1]. Moreover, malignant lymphoma of the uvula is exceedingly rare. We encountered a primary malignant lymphoma of the uvula and describe its clinical findings, MRI and treatment.

Case report

A 80-year-old Japanese woman presented with a one month history of oral discomfort. Physical examination revealed uvular swelling with a smooth surface that was elastic hard. This uvular mass occupied the oropharyngeal space (Figures 1 and 2). In the laryngopharynx, Waldeyer's tonsillar ring and neck, tumors and swelling of the neck lymph nodes could not be found by visual palpation, MRI, CT or echo. The biopsy examination of the uvula swelling revealed only inflammation of the mucous membranes. The patient received surgical treatment and the uvular tumor was extirpated by electric knife and coagulation with a safety margin of 2 mm (Figure 3). There was little intraoperative bleeding. Postoperatively, there was no wound infection, snuffling voice or dysphagia.

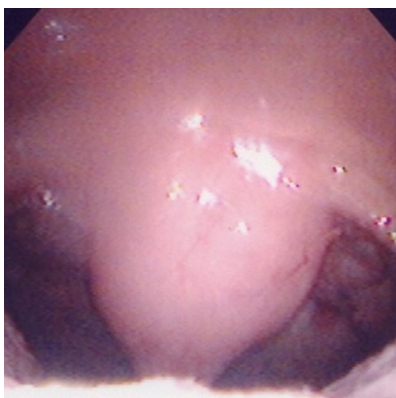


Figure 1. A uvular mass showed a smooth surface that was elastic hard.

Histological examination showed atypical lymphocytes by H&E staining and suspected malignant lymphoma (Figure 4). On the edge surrounding a mass of malignant cells could be found. For this reason, we consulted pathologists and a hematologist; follicular lymphoma was diagnosed by immunohistochemical staining (CD10:+, CD20:+, bcl-2:+). In the general examination, PET-CT revealed no abnormal accumulation in the body, and the marrow chromosome examination was normal. From the above results, our case was considered stage IA (UICC) and we added postoperative radiotherapy (33.6Gy). At 3 years after the radiation therapy, no recurrence or metastasis was found.

Discussion

Extra-nodular malignancies with initial symptoms in the oral cavity are rare. Their occurrence is 2.2% of malignant tumors and 3.5% of malignant tumors of the oral cavity [2]. Sugiyama [3] reviewed 125 extra-nodular malignancies with initial symptoms in the oral

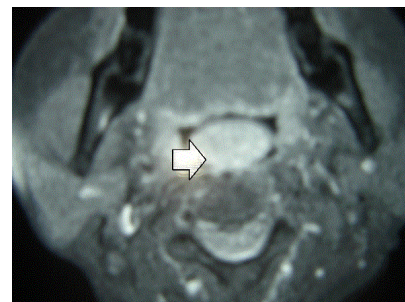


Figure 2. MRI demonstrated a mass (an arrow) occupying the oropharyngeal space.

Correspondence to: Dr. Takeshi Kusunoki, Department of Otorhinolaryngology, Juntendo University of Medicine, Shizuoka Hospital, 1129 Nagaoka Izunokuni-shi, Shizuoka 410-2295, Japan; Fax: +81-55-948-5088; E-mail: ttkusunoki001@aol.com

Key words: malignant lymphoma, uvula, immunohistochemical staining

Received: January 05, 2017; **Accepted:** January 25, 2017; **Published:** January 28, 2017

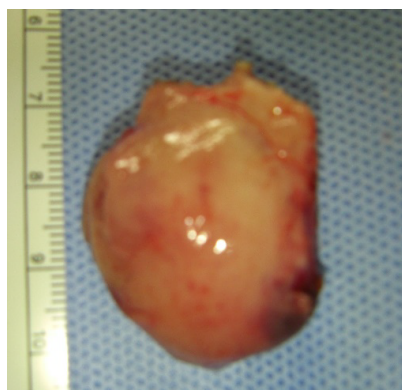

Figure 3. A specimen with a safety margin of 2 mm did not reveal malignant cells in the surrounding edges of the tumor.

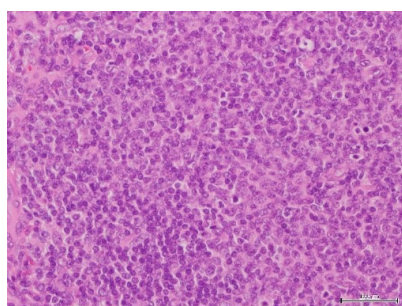


Figure 4. Histopathological findings of the uvular tumor showed proliferating atypical lymphocytes with small oval cells (H&E staining).

cavity reported in Japan. The primary site with the highest incidence was the gingiva in 47.2% of oral malignancies. In histopathology, 73% of the cases were diffuse large B cell lymphoma and 12% were MALT lymphoma. Our case was follicular lymphoma, which has a low incidence of 2.4%. Malignant lymphoma is classified by various histopathologic types and is often difficult to diagnose. In our case, Pre-operatively, the biopsy examination of the uvula tumor revealed only inflammation without malignancy. But, follicular lymphoma could be diagnosed by immunohistochemical staining (CD10:+, CD20:+, bcl-2:+) postoperatively. We suggest that an exact diagnosis by the malignant lymphoma classification would require resect enough surgical specimens for immunological study by combining key antibodies. Moreover, for the treatment as well as diagnosis it would be necessary to consult pathologists and hematologists. Mac Manus and Hoppe [4] recommended that the treatment of choice for early stage (I and II) follicular lymphomas as our case would be radiation therapy (35-50Gy). The results of their radiation therapy demonstrated actuarial survival rates of 5, 10, 15 and 20 years were 82%, 64% and 35%, respectively. Our case stage IA (UICC) underwent postoperative

radiotherapy (33.6Gy). At 3 year after the radiation therapy, no recurrence or metastasis was found.

Primary malignant lymphoma of the uvula is very rare. However, a few reports in the world have presented malignant lymphoma of the uvula accompanied by lymphoma of the neck, breast or stomach [1,5,6]. Therefore, we followed up and checked for recurrence and metastasis in the whole body and oropharyngeal area by PET-CT and hematological findings.

Declarations

Author's contributions

Takeshi Kusunoki MD: diagnosis and therapy, composition of this case report

Hirotomo Honma MD: therapy

Yoshinobu Kidokoro MD: therapy

Aya Yanai MD: therapy

Ryo Wada MD: Pathological diagnosis

Katsuhisa Ikeda MD: composition of this case report

Consent for publication

Consent for publication on the clinical details, images and histopathological examination was obtained for this case report. A copy of this document is available for review by the Editor of this journal.

Acknowledgements

The authors thank Mr. Brent Bell for checking English of the manuscript.

References

- Walker R, Heffelfinger R (2012) Low-grade B-cell lymphoma presenting as a uvular mass. *Ear Nose Throat J* 91: E22-24. [Crossref]
- Sugiyama S, Iwai T, Oguri S, Nakajima H, Koizumi T, et al. (2016) Clinical study of extra-nodal malignant lymphoma with initial symptoms in oral cavity. *Japanese Journal of Head and Neck Cancer* 42: 339-344.
- Eisenbud L, Sciubba J, Mir R, Sachs SA (1983) Oral presentations in non-Hodgkin's lymphoma: a review of thirty-one cases. Part I. Data analysis. *Oral Surg Oral Med Oral Pathol* 56: 151-156. [Crossref]
- Mac Manus MP, Hoppe RT (1996) Is radiotherapy curative for stage I and II low grade follicular lymphoma? Results of a long term follow-up study of patients treated at Atandford University. *J Clin Oncol* 14: 1282-1290.
- Singh A, Singh RK (2014) Right molar approach for uvulectomy of secondary non-hodgkins lymphoma of uvula. *Indian J Anaesth* 58: 358-359. [Crossref]
- Okabe S, Kuriyama Y, Kawanishi Y, Yahata N, Miyazawa K, et al. (2001) MALT lymphoma originating in breast and uvula. *Leuk Lymphoma* 41: 461-463. [Crossref]